LATERAL APPROACH FOR NEEDLE DECOMPRESSION IN TCCC

David W. Callaway, MD, MPA
Member, DHB T&I Subcommittee

Presenting Issues

- Needle decompression (NDC) failure rates are high.
- For a variety of operational, tactical and medical reasons, alternative NDC sites to the traditional 2nd ICS MCL may be beneficial

Question

- Should the CoTCCC consider recommending a lateral approach for needle decompression as a primary or alternative option?

Current Wording (TCCC Guidelines 110808)

"In a casualty with progressive respiratory distress and known or suspected torso trauma, consider a tension pneumothorax and decompress the chest on the side of the injury with a 14-gauge, 3.25 inch needle/catheter unit inserted in the second intercostal space at the midclavicular line. Ensure that the needle entry into the chest is not medial to the nipple line and is not directed towards the heart."

-PHTLS, Military Seventh Edition, pg 613.

Current Wording (TCCC Guidelines 110808)

Tactical Field Care

3. Breathing

a. In a casualty with progressive respiratory distress and known or suspected torso trauma, consider a tension pneumothorax and decompress the chest on the side of the injury with a 14-gauge, 3.25 inch needle/catheter unit inserted in the second intercostal space at the midclavicular line. Ensure that the needle entry into the chest is not medial to the nipple line and is not directed towards the heart.

b. All open and/or sucking chest wounds should be treated by immediately applying an occlusive material to cover the defect and securing it in place. Monitor the casualty for the potential development of a subsequent tension pneumothorax.

Current Wording (TCCC Guidelines 110808)

Tactical Field Care

18. Cardiopulmonary resuscitation (CPR)

Resuscitation on the battlefield for victims of blast or penetrating trauma who have no pulse, no ventilations, and no other signs of life will not be successful and should not be attempted. However, casualties with torso trauma or polytrauma who have no pulse or respirations during TFC should have bilateral needle decompression performed to ensure they do not have a tension pneumothorax prior to discontinuation of care. The procedure is the same as described in section 3 above.

Current Wording (TCCC Guidelines 110808)

Tactical Evacuation Care

2. Breathing

a. In a casualty with progressive respiratory distress and known or suspected torso trauma, consider a tension pneumothorax and decompress the chest on the side of the injury with a 14-gauge, 3.25 inch needle/catheter unit inserted in the second intercostal space at the midclavicular line. Ensure that the needle entry into the chest is not medial to the nipple line and is not directed towards the heart.

b. Consider chest tube insertion if no improvement and/or long transport is anticipated.

Current Wording (TCCC Guidelines 110808)

17. CPR in TACEVAC Care

a. Casualties with torso trauma or polytrauma who have no pulse or respirations during TACEVAC should have bilateral needle decompression performed to ensure they do not have a tension pneumothorax. The procedure is the same as described in section 2 above.

b. CPR may be attempted during this phase of care if the casualty does not have obviously fatal wounds and will be arriving at a facility with a surgical capability within a short period of time. CPR should not be done at the expense of compromising the mission or denying lifesaving care to other casualties.

Proposed Change: TFC

3. Breathing

a. In a casualty with progressive respiratory distress and known or suspected torso trauma, consider a tension pneumothorax and decompress the chest on the side of the injury with a 14-gauge, 3.25 inch needle/catheter unit inserted in the second intercostal space at the midclavicular line. Ensure that the needle entry into the chest is not medial to the nipple line and is not directed towards the heart. **An acceptable alternate site is the 4-5th intercostal space at the anterior axillary line.**

b. All open and/or sucking chest wounds should be treated by immediately applying an occlusive material to cover the defect and securing it in place. Monitor the casualty for the potential

Proposed Change: TACEVAC

2. Breathing

a. In a casualty with progressive respiratory distress and known or suspected torso trauma, consider a tension pneumothorax and decompress the chest on the side of the injury with a 14-gauge, 3.25 inch needle/catheter unit inserted in the second intercostal space at the midclavicular line. Ensure that the needle entry into the chest is not medial to the nipple line and is not directed towards the heart. **An acceptable alternate site is the 4-5th intercostal space at the anterior axillary line.**

b. All open and/or sucking chest wounds should be treated by immediately applying an occlusive material to cover the defect and securing it in place. Monitor the casualty for the potential development of a subsequent tension pneumothorax.

Proposed Change: TACEVAC

17. CPR

a. Casualties with torso trauma or polytrauma who have no pulse or respirations during TACEVAC should have bilateral needle decompression performed to ensure they do not have a tension pneumothorax. The procedure is the same as described in section 2 above.

b. CPR may be attempted during this phase of care if the casualty does not have obviously fatal wounds and will be arriving at a facility with a surgical capability within a short period of time. CPR should not be done at the expense of compromising the mission or denying lifesaving care to other casualties.

NDC: Background

NDC: Background

- Tension pneumothorax was found to be the cause of death in 3-4% of combat fatalities in the Vietnam Wound Data and Munitions Effectiveness Team (WEDMET) data. (McPherson 2006)
- OIF/OEF: rates lower
  - Why?
    - Better data collection, body armor and needle decompression
- But unrelieved tension pneumothorax continues to contribute to preventable deaths in U.S. combat casualties. (Harcke 2007, Holcomb 2007)

NDC: Background

- Prehospital needle decompression (NDC) may be lifesaving for combat casualties torso trauma. (Butler 1996, Kotwal 2011)
- NDC potentially lifesaving when performed by paramedics in selected civilian trauma patients (Davis 2005, Eckstein 1996)
- Procedure Incidence 0.2-1.7% (Eckstein 1998)
- Failure rates for anterior needle decompression with 2 inch catheters has been reported to be between 30-50% (Barton 1995; Davis 2005; Ball 2010)
- Rare but significant potential complications from procedure

NDC: Complications

- Failure of the attempted NDC may result in the death of the casualty. (Harcke 2007)
- Although unusual, significant and life threatening complications may be associated with NDC. (Riwoe 2011, Butler 2003)
  - Pulmonary artery injury and cardiac tamponade have been reported with NDC performed in the midclavicular line. (Butler 2003)
  - Laceration of the subclavian artery has been reported as a complication of attempted NDC. (Riwoe 2011)
- Because of the complications noted at the current site for NDC, authors have recommended using the 3rd or 4th ICS at the MAL as an alternate site. (Riwoe 2011)

NDC: Complications

- **Biggest: Not decompressing Tension PTX**
- Potential Complications
  - Anterior
    - Internal mammary artery injury
    - Cardiac injury
    - Great vessel injury
  - Lateral
    - Cardiac injury (if significant cardiomegaly; and left sided procedure)
    - Long thoracic nerve injury
    - Liver/spleen puncture
- Netto (2008)
  - Prospective trial, 1135 trauma patients
  - 598 with potential indication (e.g. torso trauma)
  - N= 17 patients with 18 ND→ All indicated
  - 17/18 (94%) within Cardiac Box
  - 8/18 (44%) medial to MCL (though no major complications)

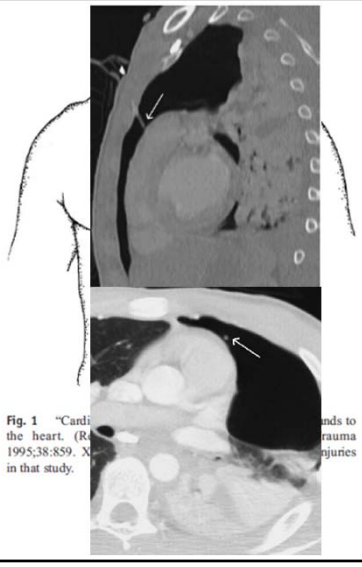

Fig. 1 "Cardi nds to the heart. (R rauma 1995;38:859. X njuries in that study.

NDC: Failure Rates

- Why ND fail
  - Training and improper technique
  - Needle/catheter length
  - Catheter location
  - Catheter kinking
  - Muscle mass
  - Blood clot in catheter
- ND challenges in tactical environment
  - Exposure
    - Equipment/Body armor
    - Hypothermia prevention
  - Anatomy and physiology
    - Muscle mass
  - Threat
    - Requirement for rapid interventions

NDC: Failure Rates

- Why ND fail
  - Training and improper technique
  - **Needle/catheter length**
  - **Catheter location**
  - Catheter kinking
  - Muscle mass
  - Blood clot in catheter
- ND challenges in tactical environment
  - Exposure
    - Equipment/Body armor
    - Hypothermia prevention
  - Anatomy and physiology
    - Muscle mass
  - Threat
    - Requirement for rapid interventions

Catheter Length

- The Advanced Trauma Life Support course currently recommends that needle decompression be performed with **a 5 cm catheter**, placed in the 2nd ICS, at the midclavicular line. (Korteek 2008)
- Several studies suggest that a 5 cm catheter may be too short to be optimal for NDC at 2 ICS MCL or 4-5 ICS AAL. (Ball 2010, McLean 2010, Stevens 2009, Rathinam 2008, Wax 2007, Givens 2004, Britten 1996)
- Previously used 5 cm (2-inch) needles were inadequate to penetrate the chest wall and were associated with several fatalities in U.S. Combat fatalities at Dover. (Harcke 2007)
- Accordingly, an 8 cm needle is now recommended in TCCC. (Butler 2009, Butler 2010)

NDC: Location

- The Advanced Trauma Life Support course currently recommends that needle decompression be performed with a 5 cm catheter, placed **in the 2nd ICS**, at the midclavicular line. (Korteek 2008)
- One study of 17 attempted prehospital NDCs in Canada found that 44% were performed too medially (Netto 2008)
- Observational study of 25 Irish EM physicians of varying experience demonstrated that although most (88%) could name the site where the needle should be placed, many (40%) could not correctly mark this spot on a human volunteer (Ferrie 2005).
- Inaba found that NDC was done at the correct location in 100% of attempts at the 4-5th ICS AAL, but in only 58% of attempts at the traditional second intercostal location. (Inaba 2011)
- Chest X-rays of tension pneumothorax typically display a marked shift of the ipsilateral lung (and the heart when the pneumothorax is left-sided) away from the lateral chest wall and towards the mediastinum.

NDC: Location

- ATLS recommends the 5th ICS just anterior to the MAL as the primary site for tube thoracostomy. (Korteek 2008)
- Anatomy: the 5th ICS is located at the level of the nipple in young, fit males. The AAL is located at approximately the lateral aspect of the pectoralis major muscle, making this location easy to identify.
- Moving the decompression site more laterally and slightly inferior to the 4-5th ICS at the anterior axillary line (AAL) would thus be expected to reduce complications resulting from this procedure (Inaba 2011)
- Execution: In a tactical situation, the lateral approach may be faster and safer given body armor configuration and ability to reassess.

Summary

- Currently, needle decompression is recommended as a Combat Lifesaver (CLS), Combat Medic (CM), and Combat Paramedic (CPM) Level Skill.
- Two major practice guidelines, Prehospital Trauma Life Support (PHTLS) and Special Operations Forces Tactics, Techniques and Procedures (SOF TTP), recommend AAL 4-5th ICS as acceptable alternative site for needle decompression of tension pneumothoraces.
- No prospective studies or case series were found that documented the relative safety or efficacy of using the 2nd ICS at the MCL as opposed to the 5th ICS at the AAL.

Summary

Oxford Centre for Evidence-based Medicine Levels of Evidence (March 2009)

- Level of evidence: 4 (Case-series and poor quality cohort and case control studies)
  - In support of 2nd ICS MCL
  - In support of 4-5th ICS AAL

Summary

- *Non- inferiority:*
  - No definitive literature was found that establishes the superiority of the 2nd intercostal space at the midclavicular line over the 4-5th intercostal site at the anterior axillary line as the preferred site for needle decompression of a presumed tension pneumothorax.
  - No adverse safety data exists regarding the lateral approach for NDC
  - All current data suggests that the 8cm catheter placed at the 4-5th ICS AAL will be effective for the majority of casualties.
- *Potential Superiority:*
  - The 4- 5th intercostal space at the anterior axillary line is more remote from the heart and great vessels and may reduce the incidence of complications from needle decompression.
  - The lateral approach may offer distinct tactical advantages that improve successful execution of the procedure.

Conclusions

- There is no definitive literature that establishes the superiority of the 2nd intercostal space at the mid-clavicular line over the 4-5th intercostal space at the anterior axillary line as the preferred site for needle decompression of a presumed tension pneumothorax.
- The 4-5th intercostal space at the anterior axillary line is more remote from the heart and great vessels and may reduce the incidence of complications from needle decompression as well as offer tactical advantages.

Recommendation

- CoTCCC should include recommendation that lateral approach (4-5th ICS AAL) is acceptable alternative to the traditional anterior mid- clavicular 2nd ICS and draft supporting text to that effect.

Proposed TCCC Language

In a casualty with progressive respiratory distress and known or suspected torso trauma, consider a tension pneumothorax and decompress the chest on the side of the injury with a 14-gauge, 3.25 inch needle/catheter unit inserted in the second intercostal space at the midclavicular line. Ensure that the needle entry into the chest is not medial to the nipple line and is not directed towards the heart. **An acceptable alternate site is the 5th intercostal space at the anterior axillary line.**

Discussion

References

- Ball C, Wyrzykowski A, Kirkpatrick A, et al: Thoracic needle decompression for tension pneumothorax: clinical correlation with catheter length. Can J Surg 2010;53:184-188
- Beckett A, Savage E, Pannell D, et al: Needle decompression for tension pneumothorax in Tactical Combat Casualty Care: do catheters placed in the midaxillary line kink more often than those in the midclavicular line? J Trauma 2011;71:S408-S412
- Britten S, Palmer SH: Chest wall thickness may limit adequate drainage of tension pneumothorax by needle thoracentesis. J Accid Emerg Med 1996;13:426-427
- Britten S, Palmer SH, Snow TM: Needle thoracocentesis in tension pneumothorax: insufficient cannula length and potential failure. Injury 1996;27:321-322
- Butler FK, Giebner SD, McSwain N, Salomone J, Pons P, eds: Prehospital Trauma Life Support Manual; Seventh Edition – Military Version. November 2010
- Butler FK; Tactical Combat Casualty Care: Update 2009; J Trauma 2010;69:S10-S13
- Butler KL, Best IM, Weaver L, Bumpers HL: Pulmonary artery injury and cardiac tamponade after needle decompression of a suspected tension pneumothorax. J Trauma 2003;54:610-611
- Kotwal RS, Montgomery HR, Botwal BM, et. Al. Eliminating Preventable Death on the Battlefield. Arch Surg 2011; 146 (12): 1350-58.

References

- Butler FK, Hagmann J, and Butler EG. Tactical Combat Casualty Care in Special Operations. Milit Med 161; Supplement; August 1996
- Cullinane DC, Morris JA, Bass JG, Rutherford EJ: Needle thoracostomy may not be indicated in the trauma patient. Injury 2001;32:749-752
- Davis DP, Pettit K, Rom CD, et al: The safety and efficacy of prehospital needle and tube thoracostomy by aeromedical personnel. Prehosp Emerg Care 2005;9:191-197
- Dickey N, Jenkins D: Needle decompression of tension pneumothorax and cardiopulmonary resuscitation: Tactical Combat Casualty Care Guidelines recommendation. Defense Health Board memorandum 2011-08; 11 Oct 2011
- Eckstein M, Suyehara D: Needle thoracostomy in the prehospital setting. Prehosp Emerg care 1998;2:132-135
- Givens ML, Ayoyye K, Manifold C: Needle thoracostomy: implications of computed tomography chest wall thickness. Acad Emerg Med 2004;11:211-213
- Harcke HT, Pearse LA, Levy AD, Getz JM, Robinson SR: Chest wall thickness in military personnel: Implications for needle thoracentesis in tension pneumothorax. Milit Med 2007;172:1260-1263

References

- Holcomb JB, McMullen NR, Pearse L, Caruso J, Wade CE, Oetjen-Gerdes L, Champion HR, Lawnick M, Farr W, Rodriguez S, Butler FK: Causes of Death in Special Operations Forces in the Global War on Terror. Annals of Surgery 2007;245:986-991
- Inaba K, Branco B, Eckstein M, et al: Optimal positioning for emergent needle thoracostomy: a cadaver-based study. J Trauma 2011;71:1099-1103
- Korteek JB, Al Turki SA, Ali J, et al: Advanced Trauma Life Support, 8th Edition, the evidence for change. J Trauma 2008; 64:1638-1650
- McLean A, Richard M, Crandall C, Marinaro J: Ultrasound determination of chest wall thickness: implications for needle thoracostomy. Am J Emerg Med 2010;Epub ahead of print.
- McPherson JJ, Feigin DS, Bellamy RF: Prevalence of tension pneumothorax in fatally wounded combat casualties. J Trauma 2006;60:573-578
- Mistry N, Bleetman A, Roberts K: Chest decompression during the resuscitation of patients in prehospital traumatic cardiac arrest. Emerg Med J 2009;26(10):738-740
- Netto FA, Shulman H, Rizoli SB, Tremblay LN, Brenneman F, Tein H: Are needle decompressions for tension pneumothraces being performed appropriately for appropriate indications? Am J Emerg Med 2008;26:597-602

References

- Rathinam S, Beetman A, Steyn RS: Needle thoracostomy in treatment of a tension pneumothorax. J Trauma 2008;65:964
- Riwoe D, Poncia H: Subclavian artery laceration: a serious complication of needle decompression. Emerg Med Australas 2011;23:651-653
- Sanchez L, Straszewski S, Saghir A, et al: Anterior versus lateral needle decompression of tension pneumothorax: comparison by computed tomography chest wall measurement. Acad Emerg Med 2011;Epub ahead of print
- Stevens RL, Rochester AA, Busko J, et al: Needle thoracostomy for tension pneumothorax: failure predicted by chest computed tomography. Prehosp Emerg Care 2009;13:14-17
- Sztajnkrycer M: Needle thoracostomy by non-medical law enforcement personnel: preliminary data on knowledge retention. Prehosp Disaster Med 2009;23(6):553-557
- Wax DB, Leibowitz AB: Radiologic assessment of potential sites for needle decompression of a tension pneumothorx. Anesth Analg 2007;105:1385-1388
- Imme Zengerink, Peter R. Brink, Kevin B. Laupland, et al. Needle Thoracostomy in the Treatment of a Tension Pneumothorax in Trauma Patients: What Size Needle? J Trauma. 2008;64:111–114.

Backup Slides

The data

Ultrasound –v- CT Scan

- Britten et al. *Injury* 1996
  - Male (29): CWT 2.2-4.4 (Mean 3.3cm)
    - 62%> 3cm
  - Women (25): CWT 1.3-5.2 (Mean 3.0 cm)
    - 52% > 3cm
- McLean et al. *AJEM* 2011

Table 1 Comparison of male and female subjects

	Male		Female		*P*
	Mean	95% CI	Mean	95% CI	
Height (m)	1.75	1.73-1.78	1.67	1.64-1.7	<.01
Weight (kg)	85.6	79.57-91.62	83.18	72.04-94.33	.69
Chest circumference (cm)	42.61	41.12-44.09	41.63	41.63-38.99	.5
BMI	27.69	26.14-29.25	30	25.78-34.22	.29
Anterior CWT (cm)	2.09	1.91-2.26	2.26	1.74-2.69	.52
Lateral CWT (cm)	2.36	2.1-2.61	2.47	1.99-2.94	.67

Ultrasound- based studies

- Problem is that we know this is not accurate in our population (Harcke, 2007)
- US studies tend to have lower CWT than CT
  - Compression
  - Measuring technique
  - Positioning?

CT based studies

Givens, et al. (2004)
Wax and Leibowitz (2007)
Sanchez, et al. (2011)
Inaba, et al. (2011)

Overview

- Probably the best model at the moment
- Mixed data on depth and on recommended location

ACAD EMERG MED • February 2004, Vol. 11, No. 2 • www.aemj.org 211

Needle Thoracostomy: Implications of Computed Tomography Chest Wall Thickness

Melissa L. Givens, MD, Karen Ayotte, MD, Craig Manifold, DO

- Methods: 111 convenience sample, CT- based
- Results:
  - 2nd ICS:
    - Males (79): 4.16 cm
    - Females (21): 4.9 cm
  - Minimum CWT: 2.2cm
  - Maximum CWT: 8.2 cm
  - NOTE:
    - 12/110 > 6cm
    - 25/110 > 5 cm
- Conclusion: 5cm catheter will only penetrate 75% of victims

Radiologic Assessment of Potential Sites for Needle Decompression of a Tension Pneumothorax

(Wax and Leibowitz. Anesth Analg 2007;105:1385–8)

- Methods: 100 adults (58 male, 42 female), CT- based study
- Results:
  - Midhemithoracic line (MHL): 3.1cm
  - Anterior axillary line (AAL): 2.6 cm
  - Midaxillary line (MAL): 3.5 cm
- Conclusions:
  1. Should attempt at MHL ("safest")
  2. Right safer than left 2/2 higher # of major soft tissue structures

Hercke, Milit Med 2007;172:1260-1263

- Methods:
  - CT based study of100 active duty, deployed males
- Results:
  - 2nd ICS: 5.36cm CWT
- Conclusions:
  - 8cm catheter should be utilized

NOTE: CoTCCC has endorsed 8cm catheter recommendations

Academic Emergency Medicine
Official Journal of the Society for Academic Emergency Medicine

ORIGINAL RESEARCH CONTRIBUTION

Anterior Versus Lateral Needle Decompression of Tension Pneumothorax: Comparison by Computed Tomography Chest Wall Measurement

Leon D. Sanchez, MD, MPH, Shannon Straszewski, MD, Amina Saghir, MBBS, Atif Khan, MBBS, Erin Horn, MD, Christopher Fischer, MD, Faisal Khosa, MD, and Marc A. Camacho, MD

ACADEMIC EMERGENCY MEDICINE 2011; 18:1022–1026

Methods: 159 trauma patients, retrospective

Results:

- 2nd ICS MCL: 4.63cm (R)/ 4.52cm (L)
- 4th ICS: 6.37 (R)/ 6.21 (L) cm
- 5th ICS: 5.38 (R)/ 5.29 (L) cm

Conclusions:

1. CWT is thinner at 2nd ICS→ better success
2. 2nd ICS "safer site"

Optimal Positioning for Emergent Needle Thoracostomy: A Cadaver-Based Study

Kenji Inaba, MD, FRCSC, FACS, Bernardino C. Branco, MD, Marc Eckstein, MD, David V. Shatz, MD, Matthew J. Martin, MD, Donald J. Green, MD, Thomas T. Noguchi, MD, and Demetrios Demetriades, MD, PhD

(*J Trauma.* 2011;71: 1099–1103)

TABLE 1. Summary of the Outcomes

	Fifth Intercostal Space		Second Intercostal Space	
	Entered the Chest (Y/N)	Wall (cm)	Entered the Chest (Y/N)	Wall (cm)
Right hemithorax	100.0% (20/20)*	3.6 ± 1.0; (3.5), (2.1, 4.9)*	60.0% (12/20)	4.5 ± 1.1; (4.7), (3.1, 6.2)
Left hemithorax	100.0% (20/20)*	3.5 ± 0.9; (3.3), (2.1, 4.8)*	55.0% (11/20)	4.4 ± 1.1; (4.4), (2.8, 6.1)
Overall	100.0% (40/40)*	3.5 ± 0.9; (3.4), (2.1, 4.9)*	57.5% (23/40)	4.5 ± 1.1; (4.5), (2.8, 6.2)

* p-values are significantly different ($p < 0.05$).
Continuous variables were reported as mean ± SD; (median), (range). Values were reported in centimeters. The p-values for categorical variables were derived from Fisher's exact test; p-values for continuous variables were derived from Mann-Whitney U test.

- Methods:
  - 20 cadavers (14 male, 6 female); 40 attempts at each site
  - 2nd ICS with 14g, 5cm Catheter
  - 5th ICSwith 14g, 5cm Catheter
- Results:
  - Above
  - 2nd ICS (Success rates: Males 75%, Females 16.7%)
  - Males: CWT lower in 5th ICS by 0.9cm
- Conclusion: Lateral 5th ICS better approach

Anterior

- Location:
  - Midclavicular (MCL) or Midhemithorax lin (MHL)
  - 2nd Intercostal space

Lateral

- Location
  - 4-5th ICS
  - Anterior Axillary line (AAL)
  - Midaxillary line (MAL)

Anatomy: Anterior Approach

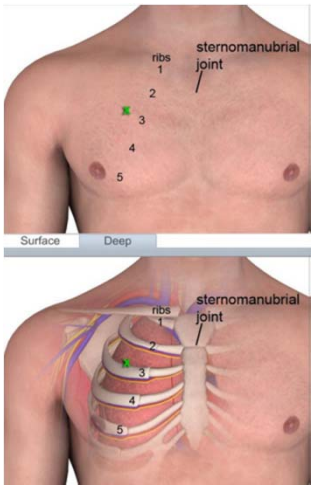

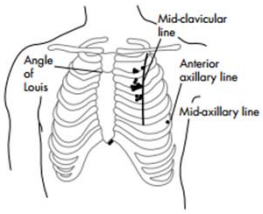

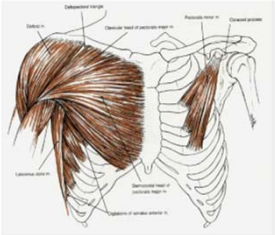
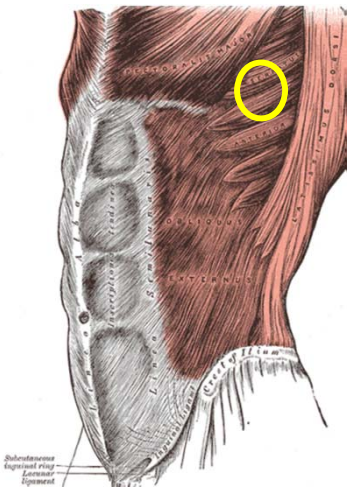
Anatomy: Lateral Approach